

## Isolated Jejunal Perforation Following Blunt Abdominal Trauma- Diagnostic Dilemma

Dr. R. Rama Krishna Naik, M.S<sup>1</sup>, Dr. Sarada M.S<sup>2</sup>, Dr. V. Sureka<sup>3</sup>

<sup>1,2</sup>Associate Professor Of General Surgery Department, Kurnool Medical College, Kurnool.

<sup>3</sup>Postgraduate In General Surgery Department, Kurnool Medical College, Kurnool.

---

**Abstract:** Small bowel injuries are the third most common injuries in BAT, occur in less than 1% of the BAT patients. <sup>[1,2]</sup> Isolated jejunal perforation (IJP) in blunt abdominal trauma (BAT) is uncommon and most often seen after motor vehicle accidents. There are higher chances of missing IJP in BAT, as majority of cases are due to solid organ injury, which are managed conservatively, and thus there is delay in diagnosis of IJP, leading to significant morbidity and mortality. Our study is a retrospective analysis of 20 patients, conducted at government general hospital, Kurnool, for duration of one year, sharing our experience regarding management of IJP in Blunt abdominal trauma patients. Exploratory laparotomy was performed and cases were managed accordingly. The diagnosis of traumatic IJP is challenging. For most favourable results, strict monitoring, high index of clinical suspicion and the help of available appropriate diagnostic tools like DPL/FAST are mandatory.

**Keywords:** Abdomen; blunt trauma; injuries; intestinal tract; jejunum

---

### I. Introduction

Isolated jejunal perforation (IJP) in blunt abdominal trauma (BAT) is uncommon and most often seen after motor vehicle accidents. Small bowel injuries are the third most common injuries in BAT, occur in less than 1% of the BAT patients. <sup>[1,2]</sup>

Mechanisms of small bowel injuries with blunt trauma include shearing forces, compression forces and bursting injury. Punctate or slit like perforations often occurring on the antimesenteric border are the consequences of raised intraluminal pressure in a fluid or air filled loops of bowel referred as blow out perforations. <sup>[3]</sup>

### II. Aims and objectives

Incidence of IJP in BAT is infrequent; the objective of this work is to review our experience and describe the clinical presentation of IJP.

### III. Methods

20 patients diagnosed with IJP in BAT between August 2014 to June 2016 in the department of General Surgery, GGH, Kurnool, were retrospectively reviewed in order to share our experience with IJP. Exploratory laparotomy was performed and cases were managed accordingly.

Data obtained from 20 cases included demographics and clinical features, examined for significant findings such as abdominal pain, vomiting, fever, and the relevant investigations were done.

### IV. Results

Between July 2014 to July 2016, 20 patients (14 males, 6 females; average age – 35yrs range 25 to 45yrs) were diagnosed with IJP in BAT.

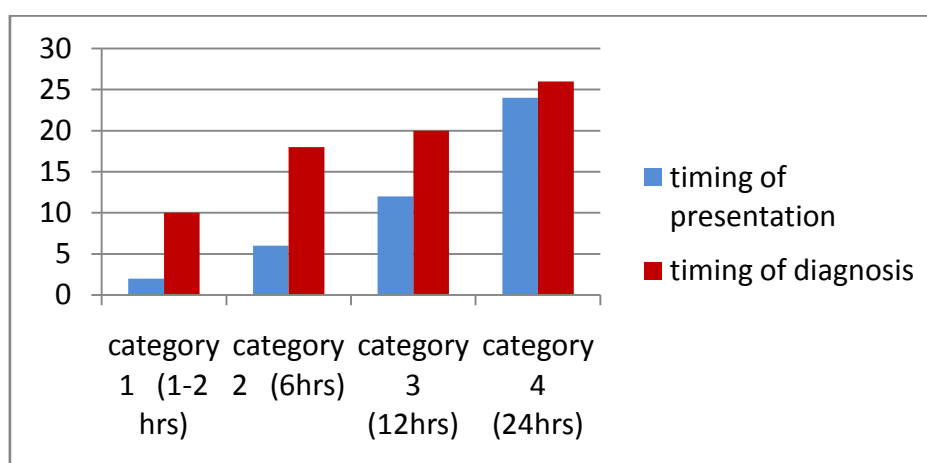
Mode of injury in 15 patients is road traffic accidents and in remaining 5 patients is assault. 7 patients presented immediately (1-2hours), 5 patients presented after 6hrs, 5 patients presented after 12hrs and 3 patients presented 24hrs after blunt abdominal trauma to our hospital.

Pain abdomen is the leading symptom in all 20 patients. Clinically Bruises noted in anterior abdominal wall in 4 patients and abdominal tenderness was the commonest finding in all patients.

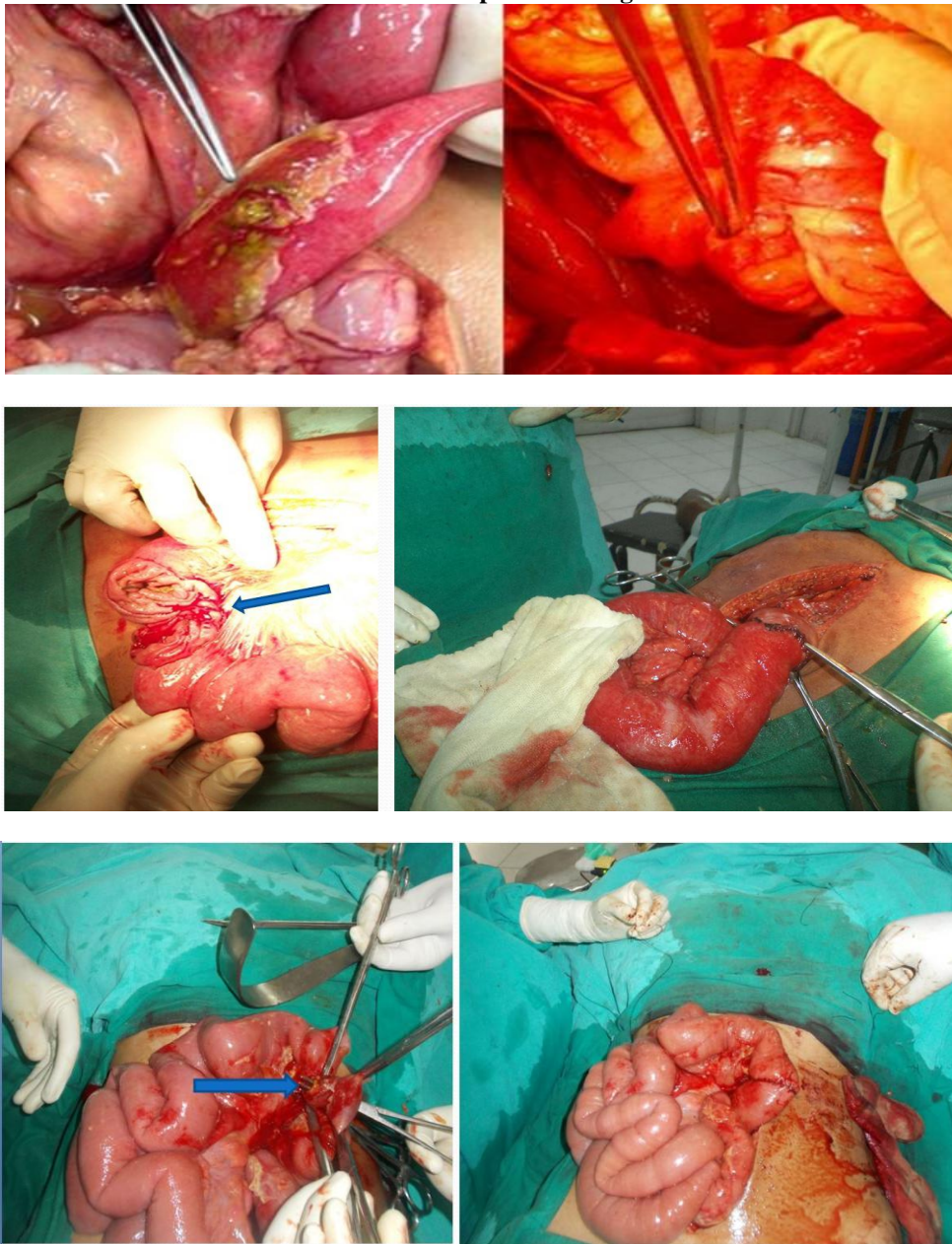
X-ray erect abdomen was done in all patients, pneumoperitoneum detected in 4 patients and the remaining patients were started on conservative treatment and CECT abdomen was planned. Ultrasound abdomen was done in all patients it is normal in 7 patients who presented immediately after BAT, in rest of the patients free fluid noted in peritoneal cavity. CECT abdomen done in selected cases (16 cases); who were planned for conservative management. In 13 cases pneumoperitoneum and free fluid noted; only free fluid noted in 3 cases. Laparotomy was done in all cases. 2 cases required resection and anastomosis and remaining cases primary closure of IJP done. Wound infection was noted in 7 patients, which was treated accordingly. Postoperative stay period on an average was around 10 days.

Clinical data of twenty patients with IJP in BAT

S. no	Age (yr)	Sex	Mode of injury	Timing of presentation (hrs)	Symptoms	X-ray erect abdomen	USG abdomen	CECT abdomen	Timing of diagnosis after BAT (hrs)	Treatment
1	25	F	RTA	6	Pain abdomen	NAD	Free fluid	Free fluid	16	Primary closure
2	28	F	RTA	Immed	Pain	NAD	Free fluid	Free fluid	10	Primary closure
3	32	M	Assault	24	Pain + fever + distension	Pneumoperitoneum	Free fluid	Not done	26	Resection & Anastomosis
4	26	M	RTA	6	Pain	NAD	Free fluid	Pneumo & free fluid	18	Primary closure
5	45	M	RTA	Immed	Pain	NAD	NAD	Free fluid	8	Primary closure
6	40	M	RTA	12	Pain + fever	NAD	Free fluid	Free fluid	18	Primary closure
7	29	M	Assault	6	Pain	NAD	NAD	Free fluid	16	Primary closure
8	37	M	RTA	Immed	Pain	NAD	NAD	Free fluid	9	Primary closure
9	34	F	RTA	12	Pain + fever	NAD	Free fluid	Free fluid	20	Primary closure
10	36	M	RTA	Immed	Pain	NAD	NAD	Free fluid	10	Primary closure
12	45	M	RTA	6	Pain abdomen	NAD	Free fluid	Free fluid	17	Primary closure
13	25	M	Assault	Immed	Pain abdomen	NAD	NAD	Pneumo & free fluid	10	Primary closure
14	27	F	RTA	24	Pain, vomiting, fever, distension	Pneumoperitoneum	Free fluid	Not done	26	Resection & Anastomosis
15	29	F	RTA	Immed	Pain	NAD	NAD	Free fluid	11	Primary closure
16	33	M	RTA	6	Pain	NAD	NAD	Pneumo & free fluid	18	Primary closure
17	32	F	Assault	12	Pain, vomiting, fever	NAD	Free fluid	Pneumo & free fluid	19	Primary closure
18	34	M	RTA	12	Pain, vomiting, fever	Pneumoperitoneum	Free fluid	Not done	18	Primary closure
19	28	F	Assault	24	Pain, vomiting, fever	Pneumoperitoneum	Free fluid	Not done	26	Primary closure
20	30	M	RTA	Immed	Pain	NAD	Free fluid	Free fluid	9	Primary closure



**Intra operative images**



**V. Conclusion**

The diagnosis of traumatic IJP is challenging, as the signs and symptoms of peritonitis appear in a later time. Physical examination was found to be reliable only in 30% of BAT cases.[1]. The presence of pneumoperitoneum in erect X-ray abdomen after traumatic small bowel injury is the exception rather than the rule. CECT abdomen is the gold standard investigation for the assessment of BAT.

A high index of suspicion, repeated clinical examination and proper utilization of investigational tools definitely helps in diagnosing these cases at an earlier period.

Although there is no consensus in the literature regarding the effects of delay in treatment of small bowel injury in BAT, the widely accepted position is that the sooner treated, the lower the morbidity for the patient.

**VI. Discussion**

Seventy-five percent of the blunt abdominal trauma cases are caused by motor vehicle accidents [4]. Although small bowel injuries have been reported to be the third most common injuries in blunt abdominal trauma, they occur in less than 1% of the blunt trauma patients<sup>[5,6]</sup>. The mechanisms of small bowel injuries with blunt trauma include shearing forces, compression between the abdominal wall and the vertebral column

and bursting injury due to a sudden increase in the intraluminal pressure. The isolated “blowout type” of rupture of the jejunum following constriction by a dhoti or fall from the stairs is extremely uncommon. This leads to a sudden increase in the intra-abdominal pressure, which in association with a full stomach, can lead to this kind of perforation. A similar mechanism of small bowel injury was caused by physical assault [7] and knee kick [8] during a game of foot ball.

Physical examination is not adequate on its own for the diagnosis of such cases, and it was found to be reliable in only 30% of the blunt trauma cases [4]. Fakhry et al [9] observed that 67.7% out of 198 patients with blunt small bowel injury, initially presented with signs or symptoms which were highly suggestive of perforative peritonitis and 84.3% were taken to the operating room without delay. X ray of the erect abdomen, USG, diagnostic peritoneal lavage and CT of the abdomen are most commonly used diagnostic aids other than physical examination. According to Burney et al [10], peritoneal lavage has proven to be sensitive for the demonstration of the haemoperitoneum, but it was found to be less reliable in the early diagnosis of intestinal injuries. The gold standard for the assessment of blunt trauma diagnosis is C T scanning, with a sensitivity of 92% and a specificity of 94%. In recent times, laparoscopy has played an important role in the diagnosis as well as in the treatment of blunt abdominal trauma. Diagnostic laparoscopy should be preferred instead of diagnostic peritoneal lavage in relatively haemodynamically stable patients. Most of the patients will be having punctuate or slit like perforations on the anti mesenteric border and so, ideally they require laparotomy and the primary closure of the perforation, with peritoneal lavage. Now, with the advent of laparoscopy, it is possible to close the perforation by using endosutures or staplers [11].

Small bowel perforation has low mortality and complication rates if it is treated before 24 hours after the injury [7]. Delayed jejunal perforation is often associated with high mortality and morbidity. Since 1990, 9 cases of isolated jejunal perforations have been reported , but the nature of the injury which was seen in our cases was different.

S.No	Year	Author	No. of cases	Nature of injury
1	1993	W K Chiang et al	1	Blunt injury
2	1994	J M Lindenmann et al	1	Blunt injury
3	2004	H Razali et al	1	Blunt injury
4	2006	I A Munshi et al	1	Blunt injury
5	2007	A K Coskun et al	1	Knee kick
6	2010	Kostantinidis C et al	1	Assault
7	2010	A Baccoli et al	3	Blunt injury

Clinical observation was not sufficient to justify the diagnosis and so the pre operative diagnosis of isolated jejunal perforation was definitely challenging. A high index of suspicion, repeated clinical examinations and the utilization of imaging modalities really helped us to diagnose these kinds of clinical entities.

### References

- [1]. Chiang WK. Isolated jejunal perforation from nonpenetrating abdominal trauma. *Am J Emerg Med* 1993;11:473-5.
- [2]. Robbs JV ,Moore SW ,Pillay SP.Blunt abdominal trauma with jejunal injury: A review. *J Trauma* 1980;20:308-11.
- [3]. Munshi IA, DiRocco JD,Khanchi G. Isolated jejunal perforation after blunt thoracoabdominal trauma. *J Emerg Med* 2006;30:393-5.
- [4]. Griswold RA, Collier HS. Blunt abdominal trauma. *Int Abstr Surg* 1961;112:309-29.
- [5]. Allen GS, Moore FA, Cox CS Jr, Wilson JT, Cohn JM, Duke JH. Hollow visceral injury and blunt trauma. *J Trauma* 1998;45:69-78.
- [6]. Neugebauer H, Wallenboeck E, Hungerford M. Seventy cases of injuries of the small intestine caused by blunt abdominal trauma: A retrospective study from 1970 to 1994. *J Trauma* 1999;46:116-21.
- [7]. Kostantinidis C, Pitsinis V, Fragulidis G. Isolated jejunal perforation following blunt abdominal trauma. *Ulus Travma Acil Cerrahi Derg* 2010; 16:87-89.
- [8]. Lindenmann JM, Schmid D, Akovbiantz A. Jejunal perforation following blunt abdominal trauma. *Schweiz Rundsch Med Prax* 1994; 83:857-60.
- [9]. Fakhry SM , Brownstein M, Watts DD, Baker CC, Oller D. Relatively short diagnostic delays [8 hours] produce morbidity and mortality in blunt small bowel injury: an analysis of time to operative intervention in 198 patients from a multicenter experience. *J Trauma*. 2000; 48:408-15.
- [10]. Burney RE, Mueller GL, Coon WW, Thomas EJ, Mackenzie JR. Diagnosis of isolated small bowel injury following blunt abdominal trauma. *Ann Emerg Med* 1983; 12:71-74.
- [11]. Townsend MS, Pelias ME. A technique for the rapid closure of traumatic small intestinal perforation without resection. *Am J Surg* 1992; 164:171-72.